

Elbow Posterolateral Synovial Fold Syndrome: A Case Series With A Modified Arthroscopic Technique

Luis Perez Carro*, Carlos Rodrigo Arriaza, Oscar Perez Fernandez, Jose Antonio Fernandez Divar and Lorena Trueba Sanchez

Abstract

Background: Posterolateral synovial fold syndrome is a rare entity on elbow pathology. Careful evaluation of clinical presentation and radiological imaging is essential to obtain the diagnosis. Treatment is usually resection of the synovial fold with arthroscopy.

Objective: To retrospectively evaluate and review the functional outcomes, findings and results after arthroscopic surgery in a case series of patients with posterolateral synovial fold syndrome treated with a modified arthroscopic technique.

Methods: Between 2010 and 2020, 6 patients diagnosed with posterolateral synovial fold syndrome were treated with average of 12 months follow-up (SD \pm 17.3) they were evaluated for clinical symptoms, radiological signs and arthroscopic findings. Patient outcome was assessed pre- and postoperatively by the Mayo Elbow Performance Index (MEPI), which assesses pain, ROM, stability and function. Statistical analysis was performed with the student's t-test. $P=0.05$ were considered statistically significant. The study was approved by ethics committee of Hospital Clinica Mompia, Santander, Spain.

Results: In all cases the synovial fold was swollen and thickened with some synovitis adjacent to the fold on the radio capitellar joint. Mild chondromalacia was observed on the capitellum and the posterolateral zone of the radial head. No pathology was observed at the anterior compartment of the elbow. All patients showed up a clinical improvement with the disappearance of pain and snapping and returned to physical activities. No loss of motion was observed. No complication or recurrence of the symptoms appeared during the 12month of follow-up. The preoperative MEPI score of 64.1 points (SD \pm 5.8) had significant improvement to 92.5 (SD \pm 8.2) on postoperative at 12 months of follow up.

Conclusion: Management of a symptomatic posterolateral synovial fold is successful and effective with our proposed arthroscopic technique.

Orthopedic Surgery Department. Clinica Mompia Santander, Cantabria, Spain

*Corresponding Author: Luis Perez-Carro, Orthopedic Surgery Department, Clinica Mompia, Santander, Cantabria, Spain.

Received Date: 08-16-2022

Accepted Date: 09-16-2022

Published Date: 09-30-2022

Copyright© 2022 by Carro LP, et al. All rights reserved. This is an open access article distributed under the terms of the Creative Commons Attribution License, which permits unrestricted use, distribution, and reproduction in any medium, provided the original author and source are credited.

Keywords: Synovial fold; Plicae; Elbow; Arthroscopy.

Introduction

Posterolateral synovial fold syndrome is a rare entity on elbow pathology [1]. Pain and mechanical symptoms such as snapping or a catching sensation may occur and be misdiagnosed with lateral epicondylitis, intraarticular loose body, instability, subluxation or dislocation of the medial part of the tricep tendon over the epicondyle [2-4]. This uncommon pathology is provoked by a posterolateral synovial fold with a shape of a meniscus-like structure that can become hypertrophied and swollen following trauma or repetitive activities [5]. Clarke in 1988 was the first to describe this disorder on three cases with a painful snapping elbow and successfully treated with arthroscopy [6]. After then, posterior synovial fold syndrome has been reported in multiples studies showing good results with operative treatment [3,7,8]. A careful evaluation of the clinical presentation (Pain and snapping) and MRI imaging (enlarged and thickened posterolateral synovial fold) is essential to obtain the diagnosis [4,9]. Once other common disorder has been excluded and the diagnosis is suspected the management is usually surgical. The arthroscopic technique has been described in multiple studies for the resection of the enlarged synovial fold using the traditional elbow portals and reporting good results [3,4,8]. In the institution, a variant of the traditional elbow arthroscopy technique is used for a better manage of the soft tissue and scope handling and visualization. The objective of this study is to retrospectively report the findings and results of patients with posterolateral synovial fold

syndrome treated with a modified arthroscopic technique.

Materials and methods

Between January 2007 to January 2020, all elbow cases treated with arthroscopy in the institution were retrospectively reviewed. Six elbow cases were diagnosed with posterolateral synovial fold syndrome. They were 5 males and 1 female with a mean age of 33.5 years (range 18-60 years). The main complaint was pain over the of lateral elbow. All of them had been misdiagnose and manage with conservative treatment for lateral epicondylitis in the past.

The physical exam consisted in searching for tenderness to palpation in the posterolateral anconeus soft spot, pain with terminal extension or reproducing a painful snap with flexion-pronation test described by Antuna and O'Driscoll [8]. Range of motion were complete in 5 cases and 1 patient had a deficit of 7° of extension. Only one of the patients presented a snapping sound at the end of the extension with the supination motion.

The Mayo Elbow Performance Index (MEPI) score was used to evaluate the outcomes of patients. They filled the questionnaire preoperatively and postoperatively with the help of an orthopaedic fellow. All patients had plain radiographs from the elbow to exclude arthritis, loose bodies, subluxation or dislocation. Conventional MRI was made to confirm the diagnosis of an enlarged posterior synovial fold (Figure 1).

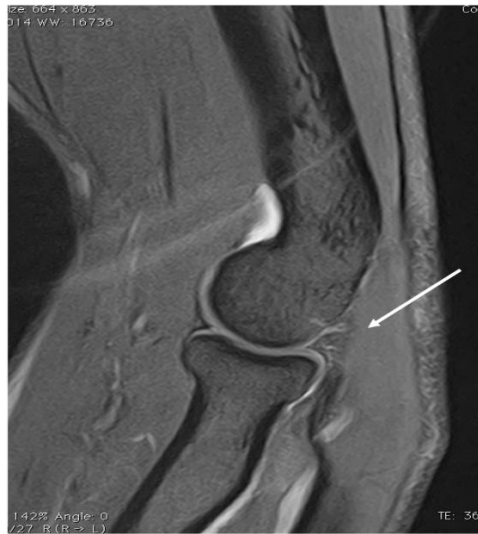

Figure 1: Sagittal magnetic resonance image showing an enlarged and thickened posterolateral synovial fold (white arrow).

An infiltration test with steroid and local anesthesia was applied with the diagnosis suspicion and in all cases the symptoms disappeared but came back at 6-8 weeks later. Operative Technique: All patients were positioned in the lateral decubitus position and used a tourniquet for the entire procedure. The pivot shift test in the posterolateral zone was made to exclude the possibility of instability [10]. The procedure was begun with the proximal anteromedial portal [11]. The sheath and trocar are inserted 2cm proximal the medial humeral epicondyle and directly anterior to the intermuscular septum avoiding the ulnar nerve and always maintaining contact with the anterior humerus to avoid risk to the median nerve.

This is a portal that offers an excellent view of the anterior compartment with a large joint arthroscope with a 30-degree vision to do the diagnostic arthroscopy. After the anterior compartment is inspected, this portal is then used only for continuously fluid flow to maintain a good distension of the capsule for

better visualization and avoid swollen soft tissue on the posterior working zone. A direct or soft spot posterior portal was then made allowing a complete view of the posterior compartment with a small joint 30-degree arthroscope. Finally, the accessory posterolateral portal was made under direct visualization of the lateral compartment and debridement and removal of the synovial fold was performed with a motorized shaver and radiofrequency device. (Figure 2,3,4). Every patient was managed ambulatory and no restriction for mobility was advised when discharge. Minimum follow-up was 12 months.

Statistical analysis was performed with SPSS Statistics Data Editor (version 22.0; IBM, Chicago, Illinois, USA). All categorical parameters were described with frequencies and mean values. The mean value of the preoperative and postoperative scoring scale of the 2 groups were compared using a paired t-test for related groups. Differences were considered significant for values $p < 0.05$.

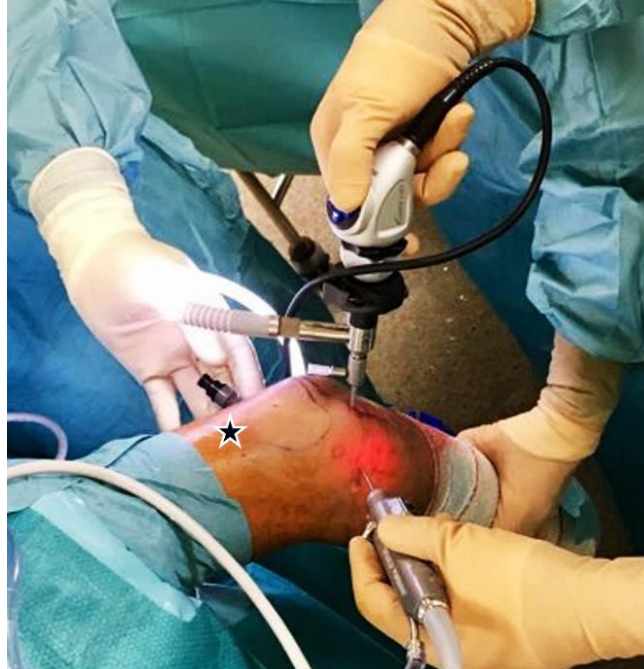

Figure 2: Left elbow, external view of the portals: The scope is in the direct or soft spot posterior portal and the instrument in the accessory posterolateral portal. Proximal anteromedial portal (black star) is used only for continuously fluid flow to maintain a good distension of the capsule for better visualization and avoid swollen soft tissue on the posterior working zone.

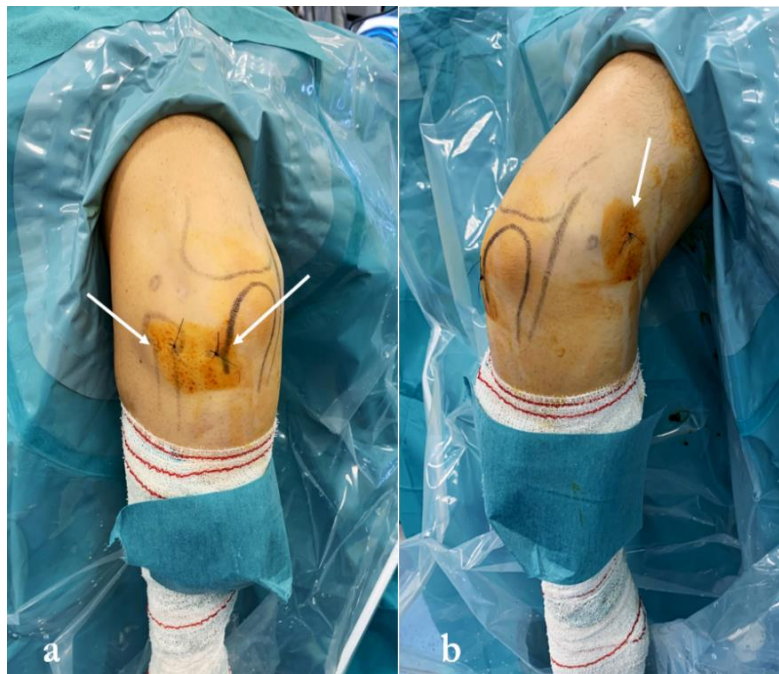

Figure 3: Left elbow. External view of the portals at the end of the surgery. a) Direct posterior or soft spot portal and accessory posterolateral portal. b) Proximal anteromedial portal.

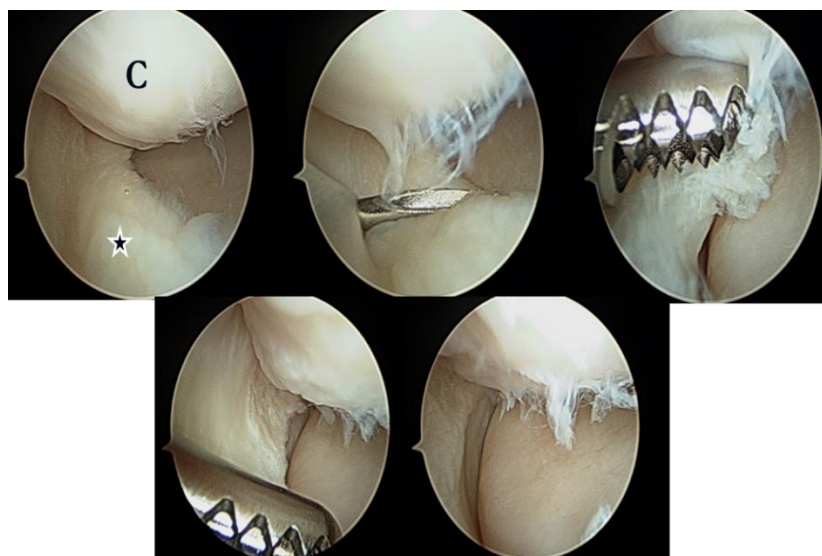

Figure 4: Arthroscopic view showing debridement and removal of a posterolateral synovial fold performed with a motorized shaver. (C, Condyle); (Black star: Posterolateral synovial fold).

Results

Arthroscopic Findings: The appearance of the synovial fold was swollen and thickened with some synovitis adjacent to the fold on the radio capitellar joint. The plicae moved back and forward from the radial head to the capitellum with no snap or click. In all cases mild chondromalacia was observed on the capitellum and the posterolateral zone of the radial head. No pathology was observed at the anterior compartment of the elbow.

No loose bodies were found in any patient. After diagnostic arthroscopy, removal of the synovial fold with a motorized shaver and radiofrequency device was performed without complications and with perfect visualization. All patients showed up a clinical improvement with the disappearance of pain and snapping and returned to physical activities. No loss of motion was observed. The patient with the limited extension recovered the motion completely. Physical therapy was not necessary in any case. Return

to work was at 2 weeks and return to sports activities without restriction at 6 weeks. No complication or recurrence of the symptoms appeared during the 12 months of follow-up. The preoperative MEPI score of 64.1 points (SD \pm 5.8) had significant improvement to 92.5 (SD \pm 8.2) on postoperative at 12 months of follow up Figure 5 and Table 1.

Discussion

Synovial folds or plicae are remnants of embryonic septa of normal articular development [1]. These folds have no known function and generally are asymptomatic [1,4]. When swollen and thickened it can produce pain and mechanical symptoms [1,8]. The posterolateral synovial fold symptoms on the elbow are nonspecific and require a careful evaluation for proper diagnosis because they can be confused with other pathology. A lot of this patients are treated with the diagnosis of lateral epicondylitis, not responding well to the treatment, most of the time with no response.

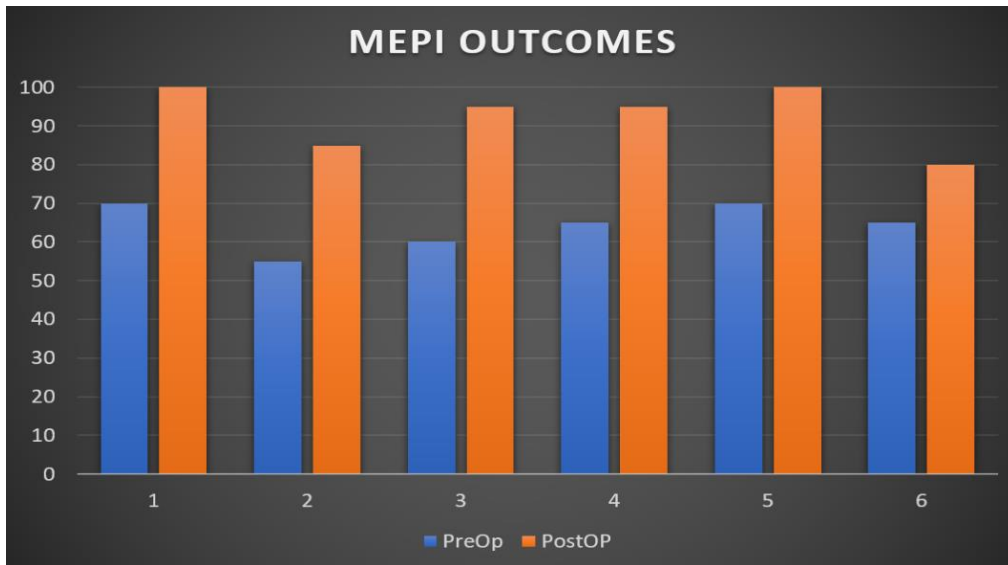


Figure 5: Arthroscopic treatment of elbow posterolateral synovial fold syndrome. Graft showing the pre and postoperative results (MIPO Score).

MEPI Outcomes					
No. of patient	Age	Gender	PreOP	PostOP	Improvement
1	32	M	70	100	30
2	30	F	55	85	30
3	18	M	60	95	35
4	26	M	65	95	35
5	60	M	70	100	30
6	35	M	65	80	15
Mean value	33.5		64.2	92.5	29.2*

Table 1: Arthroscopic treatment of elbow posterolateral synovial fold syndrome. Data of the patients and pre and postoperative MIPO Scores. *90 points or more=excellent, 75-89 point=good, 60-74 points=fair, and less than 60 points=poor. *P Value <0.05.

Ruch et al presented a case series of ten patients with symptomatic posterolateral synovial fold syndrome who were all initially misdiagnosed with lateral epicondylitis [12]. After failed conservative management all patients underwent arthroscopic resection that led to painless motion. All of our cases were misdiagnosed with lateral epicondylitis in the past and treated with non-operative management with a non-favorable outcome.

A steroid infiltration test was used to help confirm the diagnosis having a good response temporarily in all of them. After arthroscopic resection of the enlarged synovial fold, the pain disappeared showing permanent improvement in all patients. Antuna and O'Driscoll reported that 14 patients complained of painful snapping on the poster lateral elbow [8]. They all had a thickened synovial fold that would snap back and

forward over the radial head usually associated with chondromalacia. After arthroscopic surgery twelve patients showed complete relief of symptoms, one patient had associated a posterolateral instability that did not improved and one patient had recurrence of the pain after 4 years which persisted despite the 2 subsequent arthroscopies. Clarke reported a three-case series of snapping elbow that showed chondromalacia on the radial head in all cases [6]. They all resolved with resection of the synovial fold. Kim et al reported 12 throwing athletes and golfers suffering of posterolateral impingement caused by an enlarged synovial fold. 7 patients presented the catching and clicking symptoms, only 3 cases would be positive with the flexion-pronation test [3].

In the current case series, the predominant symptom was pain over the posterolateral soft spot (100%). None of the patients had instability problems when evaluated during the surgery and consider this an important step to rule out the instability differential diagnosis. The snapping was only present in 1 case (16.6%) and could be reproduce on the clinical evaluation but not with flexion-pronation test. This demonstrate that the presence of a positive flexion-pronation test is not indispensable for the diagnosis. Mild chondromalacia was seen in all cases on the radial head but also on the capitulum meaning the enlarged synovial fold may affect the entire lateral zone of the radiocapitellar joint. Our 6 cases reported clinical improvement during follow-up after the arthroscopic resection similar to the reported on the literature which continues to prove that is an excellent choice of the treatment for this disorder. The right portals and

appropriate technique are important for a successful resection of the synovial fold.

Most of the techniques described in the literature for resection of the posterolateral synovial fold use a proximal anteromedial and lateral portal to examine the anterior compartment and then resect the anterior component of the synovial fold [3,4,8]. Then a straight posterior portal for the vision and posterolateral portal for the instruments are done to finish resecting the remaining posterior synovial fold. After examination of the anterior compartment, to put the flow independently on the proximal anteromedial portal was considered and the scope and working zone on the posterior portals with small size joint instruments, to prevent a swollen region at the posterolateral soft tissue for an easy manipulation of the instruments. If not, visual difficulties and instrument handling struggles can occur in such a limited space.

Using a small joint scope and instruments are of big help for this procedure. This elbow arthroscopy is technically demanding, and a learning curve is required for a successful result. The limitation of this study is the small sample of patients due to the be a rare disorder and with difficult diagnosis. This a retrospective study and the synovial fold size on the MRI was not reported back then by the radiologist and surgeon. This is considered an important data to rule out other diagnosis.

Conclusion

Posterolateral synovial fold syndrome is a rare entity on elbow pathology. Careful evaluation of clinical presentation and radiological imaging is essential to obtain the diagnosis.

Surgical treatment is usually resection of the synovial fold with arthroscopy. The diagnosis of the posterolateral synovial fold is an important differential diagnosis in lateral painful elbow. Adequate approach with clinical and radiological evaluation is necessary to obtain the right diagnosis.

Arthroscopic management provides a successful result but requires of experience and an adequate technique.

Conflict of interest

None to report.

References

1. Cerezal L, Rodriguez-Sammartino M, Canga A, Capiel C, Arnaiz J, Cruz A, Rolón A. Elbow Synovial Fold Syndrome. *AJR Am J Roentgenol.* 2013;201(1):88-96. [PubMed](#) | [CrossRef](#)
2. Huang GS, Lee CH, Lee HS, Chen CY. A Meniscus Causing Painful Snapping of the Elbow Joint: MR Imaging with Arthroscopic and Histologic Correlation. *Eur Radiol.* 2005;15(12):2411-4. [PubMed](#) | [CrossRef](#)
3. Kim DH, Gambardella RA, Elattrache NS, Yocum LA, Jobe FW. Arthroscopic Treatment of Posterolateral Elbow Impingement from Lateral Synovial Plicae in Throwing Athletes and Golfers. *Am J Sports Med.* 2006;34(3):438-44. [PubMed](#) | [CrossRef](#)
4. Lee HI, Koh KH, Kim JP, Jaegal M, Kim Y, Park MJ. Prominent Synovial Plicae in Radiocapitellar Joints as a Potential Cause of Lateral Elbow Pain: Clinico-Radiologic Correlation. *J Shoulder Elbow Surg.* 2018;27(8):1349-56. [PubMed](#) | [CrossRef](#)
5. Duparc F, Putz R, Michot C, Muller JM, Freger P. The Synovial Fold of the Humeroradial Joint: Anatomical and Histological Features, and Clinical Relevance in Lateral Epicondylalgia of the Elbow. *Surg Radiol Anat.* 2002;24(5):302-7. [PubMed](#) | [CrossRef](#)
6. Clarke RP. Symptomatic, Lateral Synovial Fringe (plica) of the Elbow Joint. *Arthrosc J Arthrosc Relat Surg.* 1988;4(2):112-6. [PubMed](#) | [CrossRef](#)
7. Steinert AF, Goebel S, Rucker A, Barthel T. Snapping Elbow Caused by Hypertrophic Synovial Plica in the Radiohumeral Joint: A Report of Three Cases and Review of Literature. *Arch Orthop Trauma Surg.* 2010;130(3):347-51. [PubMed](#) | [CrossRef](#)
8. Antuna SA, O'Driscoll SW. Snapping Plicae Associated with Radiocapitellar Chondromalacia. *Arthrosc J Arthrosc Relat Surg.* 2001;17(5):491-5. [PubMed](#) | [CrossRef](#)
9. Choi SH, Ji SK, Lee SA, Park MJ, Chang MJ. Magnetic Resonance Imaging of Posterolateral Plica of the Elbow Joint: Asymptomatic vs. Symptomatic Subjects. *PLoS One.* 2017;12(6):e0174320. [PubMed](#) | [CrossRef](#)
10. O'driscoll SW, Bell DF, Morrey BF. Posterolateral Rotatory Instability of the Elbow. *JBJS.* 1991;73(3):440-6. [PubMed](#)
11. Stothers K, Day B, Regan WR. Arthroscopy of the Elbow: Anatomy, Portal Sites, and a Description of the Proximal Lateral Portal. *Arthroscopy.* 1995;11(4):449-57. [PubMed](#) | [CrossRef](#)
12. Ruch DS, Papadonikolakis A, Campolattaro RM. The Posterolateral Plica: A Cause of Refractory Lateral Elbow Pain. *J Shoulder Elbow Surg.* 2006;15(3):367-70. [PubMed](#) | [CrossRef](#)