

Mucormycosis: A Black Fungus- Post Covid Complications

Prithiv Kumar KR

Abstract

Human to human transmitted disease is the game of corona virus disease (COVID-19) transmission and it had been declared an emergency global pandemic that caused major disastrous in respiratory system to more than five million people and killing more than half a billion deaths across the globe. Besides lower acute respiratory syndrome, there is damage to alveolar with severe inflammatory exudation. COVID-19 patients often have lower immunosuppressive CD4+ T and CD8+ T cells and most patients in intensive care units (ICU) need mechanical ventilation, hence longer stay in hospitals. These patients have been discovered to develop fungal co-infections. COVID-19 patients develop what is known as mucormycosis a black fungal infection which is deadly leading to loss of sight and hearing and eventually death. This chapter will focus on mucormycosis, black fungus caused during post covid complications.

Keywords: COVID-19; Mucormycosis; Post Covid Complications; Intensive Care Units

Introduction

A fungal pathogen called *Aspergillus* cause devastating disease in immune compromised hosts. These hosts include haematological malignancies due to fungus being air borne, they cause wreck to lungs guarding frontline defence. Severe viral pulmonary have risen and given birth to pulmonary aspergilliosis (IPA). Most cases are IPA with 7-23% associated with fatality [1]. This IPA is compared to triple strain corona causing wreckage to lower respiratory tract infections leading to acute respiratory distress syndrome (ARDS). Triple strain corona is considerably high on patients those are in need of ICU furthering them to suffer from mucormycosis. Hence fatality rate is estimated to be high [2]. Below is the figure of mucormycosis under LPCB mount [2].

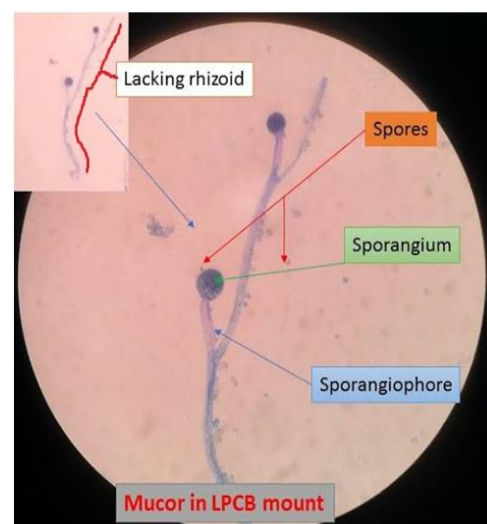


Figure 1: Figure of mucormycosis under LPCB mount.

Director, Principle Scientist- Poichyadical Stem Cell Centre for Research and Development (POSCERD), Chicago, USA

CEO, La'zer GROUP OF COMPANIES, Chicago, USA

***Corresponding Author:** Prithiv Kumar KR, Director, Principle Scientist- Poichyadical Stem Cell Centre for Research and Development (POSCERD), Chicago, USA

Accepted Date: 28-05-2021

Published Date: 28-06-2021

Copyright © 2021 by KR Kumar P. All rights reserved. This is an open access article distributed under the terms of the Creative Commons Attribution License, which permits unrestricted use, distribution, and reproduction in any medium, provided the original author and source are credited.

Case to Further Study

There is a report of 7 cases with mucormycosis. They were previously diagnosed with obstructive chronic pulmonary disease (OCPD) with symptoms of obstructive sleep apnea, insulin dependent diabetes, retinopathy, nephropathy, polyneuropathy. Severe other ones include coronary heart disease and arterial hypertension [3]. Three out of seven patients were in the age group of 60-80 and four in age category of 30-60. One of the patients with age above 60 presented with productive cough, intermittent fever, dyspnea for two weeks [4]. Medical records displayed white blood cells count was less than normal, C-reactive protein (CRP) elevated (35 mg/dl; upper limit norm 5 mg/dl), D-dimer at normal range. Chest x-ray revealed bilateral basal coarse reticular opacities. RT-PCR (Real Time Polymerase Chain Reaction) from oropharyngeal swab was positive for corona [5]. Patient admitted to ICU, showed further deterioration and hypoxemia (pO_2 46mmHg). There was high level of Creatinine, elevated neutrophils, CRP levels showed 140mg/dl, white blood cells still elevated (12.75×10^9 per L) interleukin-6 was at 365ng/ml and ferritin 450ng/ml, only lymphocytes were normal [6]. Upon second day admission in ICU, patient was further intubated and mechanically ventilated. Chest x-ray revealed progression in bilateral infiltrates with pulmonary deterioration. Further stay in ICU, endotracheal aspiration was obtained from patient and culture test was done [7]. Culture grew *Aspergillus fumigatus* voriconazole with fungal like growth. Lateral flow device reacted to *Aspergillus* specific antigen but non colonised. Serum fungal markers showed positive signs of black fungal growth. Galactomannan and 1,3- β -D-glucan marker was used to detect the fungal growth. This fungal growth was subjected to treatment, despite of efforts the patient deceased on fifth day in ICU [8]. Mucormycosis is very deadly causing loss of eyesight, hearing impairment and severe heart attack and brain cell loss. All seven patients in different age groups, mild or harsh fungal infection have died [9].

Fungal Infection after Covid-19

To put to the fact, fungal infection, Chen et al. performed this infection test in China on 99 patients out of which 5/99 were found having *Aspergillus flavus* and one case of *Candida glabrata* and three cases of *C. albicans*. After extensive search and study on mucormycosis and with little or no result of journals on this deadly fungus, one search result led to another researcher, Yang et al. found little higher percentage of people affected by this disease [10]. Many patients were treated with anti-fungal medicine but were in vain. Another German study associated with COVID-19 found 6 out of 19 patients infected with black fungal. In Netherlands, there were fresh new cases of black fungus, infecting 7 with *A. fumigatus*. In France there were 5 patients infected with *A. flavus* by tracheal aspirates culture [11]. Many incidences in that period have found covid with fungal infection increase from 16-27%, with severely ill patients dying. Most percentage of them with mucormycosis has died since the beginning on this fungal incidence began. Below figure shows penicillin in mucormycosis [12].

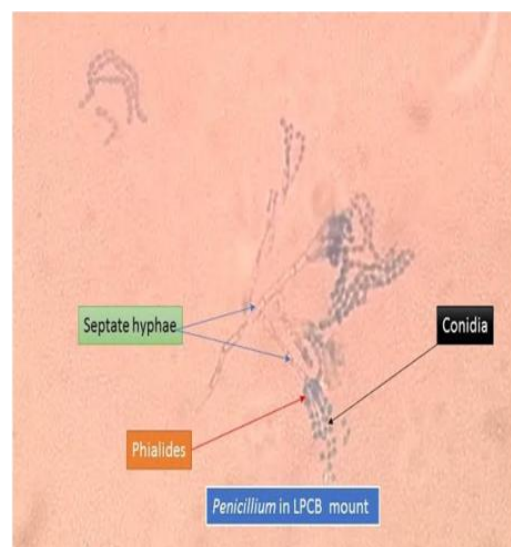


Figure 2: Figure shows penicillin in mucormycosis.

One report also suggested that despite of IPA on fungal infection the mortality rate has increased from 23% to 51%. Clinically many patients are subjected to the fungal testing attributing to severe respiratory symptoms. Some diagnosis like antibiotics has delayed this fungus. It is critical to pay attention to this mucormycosis in current COVID-19 patients. Below is the figure of *Aspergillusflavus* [13].

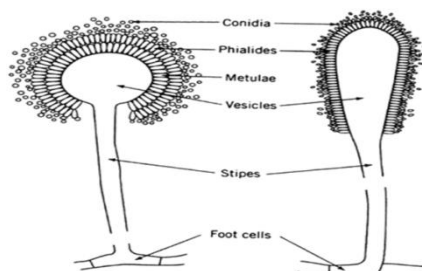


Figure 3: Figure of *Aspergillusflavus*.

Discussion for Diagnosis

It has been understood that black fungus called mucormycosis is complicating the treatment and recovery of COVID-19 patients. There were several reports of patients with invasive aspergillosis and positive growth of *Aspergillusfumigatus* and *Aspergillus-ag* in endotracheal aspirate [14]. Many patients tested has two week history of COVID-19 before and after admission in ICU, a CT scan a valuable tool for corona patients revealed, slight mold infections in chest region, but slight reversible halo, ground glass opacities also observed in some. Patients with severe influenza or halo or reversible halo show pulmonary mold leading to mucormycosis [15]. To take a step further on discussion, a diagnostic setup is suggested. The discrimination between colonization and infection were put to test. With *Aspergillus* specific LFD and certified point assay. Test showed negative to colonisation but positive to infection. The result also shows growing hyphae during invasion of fungus [16]. Serum Galactomannan shows no sensitivity in non neutrophenic patients. The LFD is the recommended method for diagnosis of invasive aspergillosis. The benefit of GM screening in COVID-19 patients shows data that attracts

attention on recently published trial. The data shows GM in serum is on the rise [17]. The new norms of European Organisation for Research and Treatment of Cancer/Mycoses Study Group showed diagnostic criteria for ICU patients due to missing host. The criteria broadly includes chest imaging of lungs and microbiological evidence of *Aspergillus* presence. Presently the influenza and aspergillosis trial shows GM in serum and bronchoalveolar lavage fluid in mycological criterium to overcome imperfect culture limitation and sensitivity of *Aspergillus*. Below is the chart for colonisation [18].

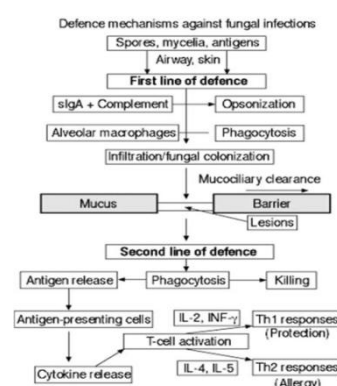


Figure 4: The chart for colonization.

The patient reported presence of fungus, increasing the risk for IPA. Viral infections like influenza or cytomegalovirus infections increase risk for IPA. There is over expression of anti-inflammatory cytokines, T-helper cells and cell mediated immune response which is impaired. This impairment is due to mold in COVID-19 patients admitted to ICU. Hence discussion concludes IPA occurrence in COVID-19 patients [19].

Etymology and Diagnosis

It has been discovered that mucormycosis has common agents such as Rhizopusspp, Mucorspp. Genera of Mucorales, varies from country to country. Mucorspp, Lichthemiaspp and Rhizopussppat 34%, 19% and 19% are common in Europe. In India Rhizopusspp is the most common causing disease Apophysomyceselegans, A. variabilis and Rhizopushomothalliusare emerging. Another species namely Apophysomyces reported in

Mexico. By inhalation of sporangiospores, mucormycosis is caused [19]. These are air borne or direct inoculation of organisms into skin or gastrointestinal tract mucosa. Recent studies suggest they are seasonal infections occurring from August to November, but patients in Australia showed mucormycosis occurring anytime with uncommon species such as non *Rhizopus* and some infected with *Apophysomyces* or *Saksenasp* localised in skin and tissues [20].

Mucormycosis has been a centre of attention all around the globe. But there seem difference in species and effect on human body differing from developed country and developing nations. In developed nation this disease is less common and seen only in patients with haematological malignancies(HM). The developing countries paint a different picture, it is common in patients with uncontrolled diabetes mellitus or trauma. In India, mucormycosis is seen in 14 out of 100000 patients. In Europe and US it is seen in 0.01 per 100000 population [21]. Below is the image of formation of mucormycosis inside lungs [21].

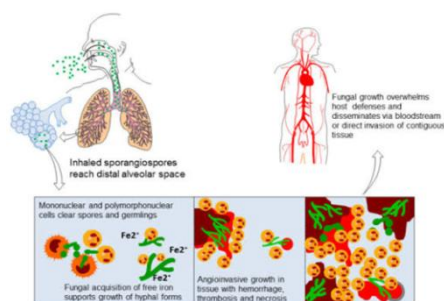


Figure 5: The image of formation of mucormycosis inside.

The percentage associated with mucormycosis in rhino-orbito- cerebral pulmonary are 27%, 20% and 18% . In Europe it is 27%, 32%, 26%. Considering patients with HM is less compared to patients in India with DM. In Mexico, 72% of people were associated with diabetes underlying malignancies, sinus and pulmonary. Below is the figure for diagnosis of mucormycosis [22].

Infections from Mucorales are usually rapid, they were initially reported in farmers from China. Some reports show they are

opportunistic fungus like *Mucor irregularis*, that has completely different epidemiology. Their infections are highly chronic but without any risk factors affecting only skin and tissue cells [23].

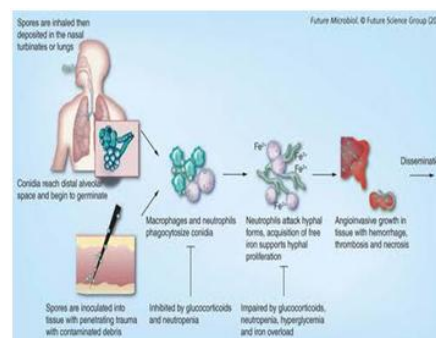


Figure 6: The figure for diagnosis of mucormycosis.

Fungal isolates such as *Rhizopus* and *Lichtheimia* along with *Mucor* were found in children in some cases. Keeping the factors of HM and malignancies such as solid organ transplant, surgery, DM and underlying many medical conditions the fungus targets the above and attacks lungs, skin, soft tissues, sino orbital and rhino cerebral region. Mortality rate for such studies were more than 60%. In Children it was 15% with certain infection [23].

Clinical Diagnosis and Possibilities

The diagnosis has prerequisite and with great deal of suspicion and recognition host, we can incur to conclusion through testing methodologies such as histology, imaging modalities, advanced molecular methods and microbiology. As a revision, rhinocerebral pulmonary is the most common clinical presentation for Mucorales with representation in soft tissues, pulmonary vessels, disseminated diseases and any other organ that shows infection [24]. Tissue necrosis is the benchmark for mucormycosis. Fungi such as *Aspergillus* or *Fusarium* show some sign. Below chart shows pathophysiology of mucormycosis [24].

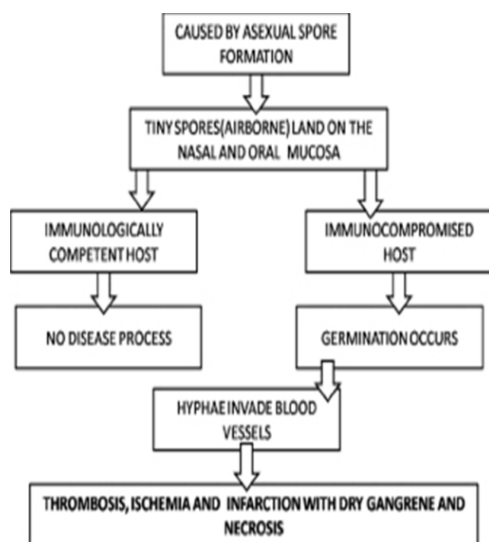


Figure 7: Chart shows pathophysiology of mucormycosis.

In many countries where tuberculosis is relevant, two infections coexist. However with diabetic patients the index is higher for invasive pulmonary mucormycosis. The list that should be considered as symptoms are cranial nerve palsy, diplopia, sinus pain, orbital apex syndrome, ulcer, preorbital swelling. In radiology, most common symptom is pleural effusion. Computerised topography(CT)scan that indicates mucormycosis is the reverse halo sign (RHS) , when sequential thoracic CT scans are performed in more than 100 patients RHS were observed in 92 patients during initial stage of disease. Hence we conclude RHS on CT scan is a strong indicator of presence of pulmonary mucormycosis. In another study of patients with lung mucormycosis, presence of RHS is common on all of them. Symptoms were centrilobular nodules, bronchial wall thickening, petribronchial consolidation with *Aspergillus* in it [25].

Another method for aggressive lab technique to identify mucormycosis is positron emission tomography-computed tomography (PET/CT) with fluorodeoxyglucose(FDG). Endobrochial ultrasound guided injection is the best and useful diagnostic tool for mucormycosis [25]. Below graph shows presence on mucormycosis and growth [25].

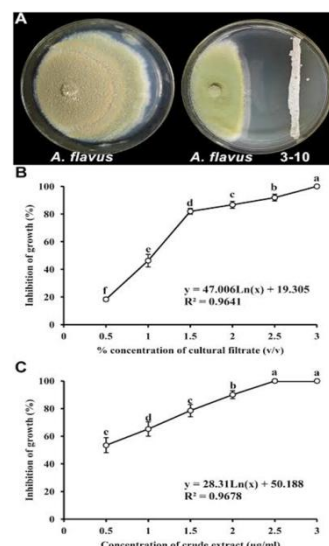


Figure 8: Graph shows presence on mucormycosis and growth.

Laboratory Work and Culture Technique

Laboratory work and culture on petridishis the effective clinical tool for mucormycosis. Below is the microscopic view of mucormycosis [25].

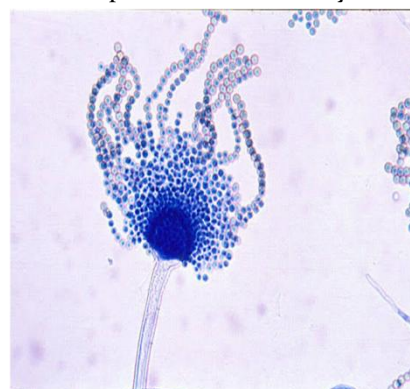

Figure 9: Microscopic view of mucormycosis.

Hypea and Mucorales have a width of 6-25 nano meters and are nonseptate and have a ribbon shaped appearance. The angle and branching are at 90 degrees and fungal element is seen at hematoxylin and eosin regions. To elevate morphology more, periodic acid Schiff or Grocott were used for silver staining to highlight hypea. Tissue hispathology shows inflammation regions, in some cases these are absent in immune suppressed patients. In cases of nerve cells, perineural invasion is present when done by tissue histopathology, but that is not the best method always, tissue

differentiation is most effective to differentiate between hyphae of *Aspergillus* and hyphae of Mucorales. It distinguishes all fungi and helps in pathogen of specimen in laboratory culture containment [26].

It is observed that Mucorales grow upto 3-7 days on fungal media, namely potato dextrose agar and Sabouraud agar incubated at 25 degrees. In some cases, it aids in yield of culture, because hyphae are friable in nature and gets damaged easily. The main target of this culture in situ hybridization is 5S and 18S ribosomal RNA sequence, hence a specific mouse monoclonal anti- Rhizomucor antibody is employed to target analysis and to react strongly on mucorales and Entomophthorales [27].

Identification of Species

Identifying species is more important for better understanding of epidemiology of mucormycosis. Mucorales fungi differentiates from *Aspergillus* fungi on culture and provides high level of accuracy in fungal identification. Test kits used are ID32C combined with positive melezitose assimilation detects *L. reisseri*. Another one is the matrix assisted laser desorption/ionization time of flight (MALDI-TOF) along with mass spectrometry [28]. Serology used are ELISA assays immunoblots and immunodiffusion tests that are invasive towards Mucorales and mucormycosis. Specific T cells were detected from above, they are used as surrogate diagnostic markers for further research. Molecular assays such as PCR restriction fragment length polymorphism analysis (RFLP), DNA sequencing of defined genes and melt curve analysis were part of assays that help in analysis of Mucorales. They targeted internal transcribed 18S rRNA genes [29].

Specificity in Cure

Multimodal approach is necessary to cure mucormycosis. Early dosage of anti-fungal agents, rapid correction of metabolic abnormalities are mandatory features. For diabetic patients, sodium bicarbonate (with

insulin) to reverse ketoacidosis regardless of whether acidosis is mild or severe, has the ability to reverse Mucorales to invade hosts.

Drugs such as corticosteroids should help in early diagnosis such as to stop tissue invasion. Mucormycosis has characteristics to invade angio vessel that leads to thrombosis and tissue necrosis. The suggestion by European conference for such harsh invasion is lipid formulation of amphotericin B. The suggested dose is 5mg/kg/day upto 10mg/kg/day for injection in central nervous system. The results conducted on patients with mucormycosis showed a response rate of 78% in week 1 to 87% on week 12 [30].

Posaconazole and isavuconazole are used as maintenance therapy dosages recommended by ECMM at dose of 200 mg q6h of oral. This has some effect on fungus and recovery rate is high. Another option is salvage treatment, combining effects of liquid amphotericin B and caspofungin or posaconazole, impact showed survival rates much higher on patients with rhino orbital cerebral mucormycosis. The use of hyperbaric oxygen to enrich cytokine environment to lower fungal cell area works at high percentage. This oxygen helps in stimulating granulocyte-macrophage colony giving way for interferon gamma response to fight the Mucorales. Final treatment can be done with the usage of drug VT-1161, an inhibitor with selective activity against fungus. They are ergosterol synthesis inhibitor and prove an additional asset to fight mucormycosis [31].

Conclusion

Mucormycosis is a disease that is rare but poses an important burden on immune compromised patients. Newly developed medications have several pathogenesis but cure to mucormycosis is still a challenge. Several methods have delayed the mortality but still poses a challenge in curing mucorales. The clinical presentation is non specific, and early diagnosis target the histopathology efficiency and it is time consuming. Direct examination of culture, molecular diagnostic techniques, PCR and situ hybridisation offer an alternate to initiation the

treatment. The management of mucormycosis depends on underlying factors such as injection of antifungal agents, surgical intervention and timely dosage of antifungal therapy.

Immunologic and metabolic profiling is the way to approach this black fungus i.e mucormycosis.

References

1. Gangneux JP, Bougnoux ME, Dannaoui E, Cornet M, Zahar JR. Invasive fungal diseases during COVID-19: we should be prepared. *J Mycol Med.* 2020. Jun;30(2):100971. [PubMed](#) | [CrossRef](#)
2. Guo L, Wei D, Zhang X, Wu Y, Li Q, Zhou M, et al. Clinical features predicting mortality risk in patients with viral pneumonia: the MuLBSTA score. *Front Microbiol.* 2019;10:2752. [PubMed](#) | [CrossRef](#)
3. Koehler P, Cornely OA, Bottiger BW, Dusse F, Eichenauer DA, Fuchs F, et al. COVID-19 associated pulmonary aspergillosis. *Mycoses.* 2020. [PubMed](#) | [CrossRef](#)
4. van Arkel ALE, Rijpstra TA, Belderbos HNA, van Wijngaarden P, Verweij PE, Bentvelsen RG. COVID-19 associated pulmonary aspergillosis. *Am J Respir Crit Care Med.* 2020. [PubMed](#) | [CrossRef](#)
5. Prattes J, Valentin T, Hoenigl M, Talakic E, Reisinger AC, Eller P. Invasive pulmonary aspergillosis complicating COVID-19 in the ICU- a case report. *Med Mycol Case Rep.* 2020. [PubMed](#) | [CrossRef](#)
6. HageChadi A, Carmona EM, Epelbaum O, Evans SE, Gabe LM, Haydour Q, et al. Erratum: Microbiological laboratory testing in the diagnosis of fungal infections in pulmonary and critical care practice. An Official American Thoracic Society Clinical Practice Guideline. *Am J Respir Crit Care Med.* 2019;200(10):1326. [PubMed](#) | [CrossRef](#)
7. Fishman JA, Grossi PA. Novel Coronavirus-19 (COVID-19) in the immunocompromised transplant recipient: #Flatteningthecurve. *Am J Transplant.* 2020. [PubMed](#) | [CrossRef](#)
8. Skiada A, Lass-Floerl C, Klimko N, Ibrahim A, Roilides E, Petrikos G. Challenges in the diagnosis and treatment of mucormycosis. *Med Mycol.* 2018;56. [PubMed](#) | [CrossRef](#)
9. Schwartz IS, Friedman DZP, Zapernick L, Dingle TC, Lee N, Sligl W. High rates of influenza-associated invasive pulmonary aspergillosis may not be universal: a retrospective cohort study from Alberta, Canada. *Clin. Infect. Dis.: Off. Publ. Infect. Dis. Soc. Am.* 2020. [PubMed](#) | [CrossRef](#)
10. Prattes J, Flick H, Pruller F, Koidl C, Raggam RB, Palfner M. Novel tests for diagnosis of invasive aspergillosis in patients with underlying respiratory diseases. *Am. J. Respir. Crit. Care Med.* 2014;190(8):922–929. [PubMed](#) | [CrossRef](#)
11. Blot SI, Taccone FS, Van den Abeele AM, Bulpa P, Meersseman W, Brusselaers N. A clinical algorithm to diagnose invasive pulmonary aspergillosis in critically ill patients. *Am. J. Respir. Crit. Care Med.* 2012;186(1):56–64. [PubMed](#) | [CrossRef](#)
12. Cornely OA, Alastruey-Izquierdo A, Arenz D, Chen SCA, Dannaoui E, Hochhegger B. Global guideline for the diagnosis and management of mucormycosis: an initiative of the European confederation of medical mycology in cooperation with the mycoses study Group education and Research consortium. *Lancet Infect. Dis.* 2019;19(12):e405–e421. [PubMed](#) | [CrossRef](#)
13. Godoy MC, Viswanathan C, Marchiori E, Truong MT, Benveniste MF, Rossi S. The reversed halo sign: update and differential diagnosis. *Br. J. Radiol.* 2012;85(1017):1226–1235. [PubMed](#) | [CrossRef](#)
14. Li Y, Xia L. Coronavirus disease 2019 (COVID-19): role of chest CT in diagnosis and management. *AJR Am. J. Roentgenol.* 2020:1–7. [PubMed](#) | [CrossRef](#)
15. Ullmann AJ, Aguado JM, Arian-Akdagli S, Denning DW, Groll AH, Lagrou K. Diagnosis and management of *Aspergillus* diseases: executive summary of the 2017 ESCMID-ECMM-ERS

- guideline. *PubMed* | [CrossRef](#) *Clinical microbiology and infection*. Off. Publ. Eur. Soc. Clin. Microbiol. Infect. Dis. 2018;24(Suppl 1):e1–e38. [PubMed](#) | [CrossRef](#)
16. Kontoyiannis DP, Azie N, Franks B, Horn DL. Prospective Antifungal Therapy (PATH) Alliance[®]: focus on mucormycosis. *Mycoses*. 2014;57: 240–246. [PubMed](#) | [CrossRef](#)
 17. Gomes MZR, Lewis RE, Kontoyiannis DP. Mucormycosis caused by unusual mucormycetes, non-Rhizopus, -Mucor, and -Lichtheimia species. *ClinMicrobiol Rev*. 2011; 24: 411–445. [PubMed](#) | [CrossRef](#)
 18. Ruhnke M, Groll AH, Mayser P et al. Estimated burden of fungal infections in Germany. *Mycoses*. 2015; 58: 22–28. [PubMed](#) | [CrossRef](#)
 19. Jung J, Kim Y, Lee HJ et al. Comparison of computed tomographic findings in pulmonary mucormycosis and invasive pulmonary aspergillosis. *ClinMicrobiol Infect*. 2015; 21: e11–684.e18. [PubMed](#) | [CrossRef](#)
 20. Liu Y, Wu H, Huang F, Fan Z, Xu B. Utility of 18F- FDG PET/CT in diagnosis and management of mucormycosis. *ClinNucl Med*. 2013; 38: e370–e371. [PubMed](#) | [CrossRef](#)
 21. Schrödl W, Heydel T, Schwartz VU et al. Direct analysis and identification of pathogenic Lichtheimia species by matrix-assisted laser desorption ionization “Time of Flight” analyzer-mediated mass spectrometry. *J ClinMicrobiol*. 2012; 50: 419–427. [PubMed](#) | [CrossRef](#)
 22. Machouart M, Larché J, Burton K et al. Genetic identification of the main opportunistic mucorales by PCR-restriction fragment length polymorphism. *J ClinMicrobiol*. 2006; 44: 805–810. [PubMed](#) | [CrossRef](#)
 23. Nyilasi I, Papp T, Csernetics Á, Krizsán K, Nagy E, Vágvölgyi C. High-affinity iron permease (FTR₁) gene sequence-based molecular identification of clinically important Zygomycetes. *ClinMicrobiol Infect*. 2008; 14: 393–397. [PubMed](#) | [CrossRef](#)
 24. Springer J, Lackner M, Ensinger C et al. Clinical evaluation of a Mucorales-specific real-time PCR assay in tissue and serum samples. *J Med Microbiol*. 2016; 65: 1414–1421. [PubMed](#) | [CrossRef](#)
 25. Ino K, Nakase K, Nakamura A et al. Management of pulmonary mucormycosis based on a polymerase chain reaction (PCR) diagnosis in patients with hematologic malignancies: a report of four cases. *Intern Med*. 2017; 56: 707–711. [PubMed](#) | [CrossRef](#)
 26. Cornely OA, Arikan-Akdagli S, Dannaoui E et al. ESCMID and ECMM joint clinical guidelines for the diagnosis and management of mucormycosis. *ClinMicrobiol Infect*. 2014; 20: 5–26. [PubMed](#) | [CrossRef](#)
 27. Rodriguez MM, Pastor FJ, Sutton DA et al. Correlation between in vitro activity of posaconazole and in vivo efficacy against Rhizopusoryzae infection in mice. *Antimicrob Agents Chemother*. 2010; 54: 1665–1669. [PubMed](#) | [CrossRef](#)
 28. Netea MG, Van der Meer JW, Kullberg BJ. Role of the dual interaction of fungal pathogens with pattern recognition receptors in the activation and modulation of host defence. *ClinMicrobiol Infect*. 2006; 12: 404–409. [PubMed](#) | [CrossRef](#)
 29. Gebremariam T, Liu M, Luo G et al. CotH₃ mediates fungal invasion of host cells during mucormycosis. *J Clin Invest*. 2014; 124: 237–250. [PubMed](#) | [CrossRef](#)
 30. Lanternier F, Poiree S, Elie C et al. Prospective pilot study of high-dose (10 mg/kg/day) liposomal amphotericin B (L-Amb) for the initial treatment of mucormycosis. *J Antimicrob Chemother*. 2015; 70: 3116–3123. [PubMed](#) | [CrossRef](#)
 31. Wiederhold NP. Pharmacokinetics and safety of posaconazole delayed-release tablets for invasive fungal infections. *ClinPharmacol*. 2016; 8: 1–8. [PubMed](#) | [CrossRef](#)